

Rose K2 IC Design Information

The Rose K IC lens design is manufactured with a larger posterior optical zone than standard lenses. It has an aspheric posterior surface incorporating aberration controlled optics and reverse geometry para-central fitting curves. The Rose K2 IC lens has a standard diameter of 11.4mm and can be supplied up to 12.0mm diameter.

Rose K2 IC Availability

It is recommended that the Rose K2 IC lens design be fitted from a diagnostic trial lens set only. This is supplied as a twenty lens diagnostic trial set. The diagnostic trial set is supplied in an 11.4 mm diameter and standard edge lift with a base curve range from 6.0mm to 6.8mm in 0.2mm steps, 6.9mm to 8.0mm steps and 8.0mm, 8.4mm and 8.6mm.

Rose K2 IC Parameter Range


Base Curve: 5.7mm to 9.0mm in 0.1mm steps
Diameter: 9.4mm to 12.0mm in 0.1mm steps
Power: +30.0D to -30.0D in 0.25 steps
Edge Lift: Standard, Increased, Double Increased, Decreased and Double Decreased.

Rose K2 IC Material

It is important that with all large diameter lenses oxygen permeability is not compromised, and the Rose KIC lens is available in Menicon Z blue tint.

R O S E K2 IC™
IRREGULAR CORNEA

irregular cornea



Rose K2 IC Indications

The Rose K2 IC contact lens for irregular corneas is a large diameter GP lens which opens up an extended range of applications such as Pellucid marginal Degeneration (PMD), Keratoglobus, Post Graft, and LASIK Induced Ecstasia with secondary applications for Nipple and Oval cones.

Pellucid Marginal Degeneration (PMD)

PMD is a bilateral corneal disorder hallmarked by a thinning of the inferior peripheral cornea typically 1 to 2mm above the inferior limbus (figure 1). It is usually restricted to the 4-8 o'clock region. The cornea will exhibit a flat area just inside this region before steepening rapidly as the cornea thins and is characterised by large degrees of central against the rule astigmatism (figure 2). Topography maps often show a pattern 'likened to two birds kissing'.

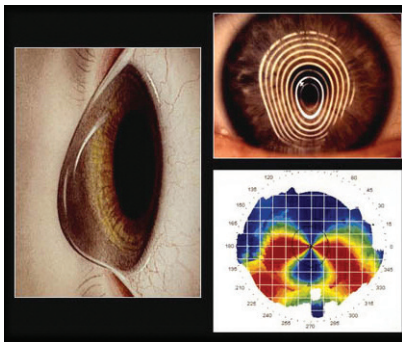


Figure 1 - Pellucid Marginal Degeneration (Courtesy of Pat Caroline)

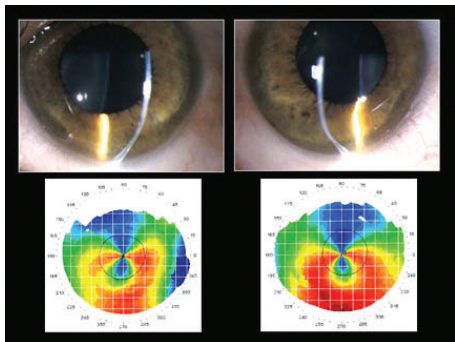


Figure 2 - PMD with high ATR astigmatism (Courtesy of Pat Caroline)

Keratoglobus

In instances of globus cones where a large area of the cornea is affected of which up to 75% is below the visual axis, then Munson's sign is usually present. This is where there is forward displacement of the lower lid by the cone on downward gaze.

Post Graft

Where patients have undergone penetrating keratoplasty or a corneal graft, then the Rose K IC lens is useful to aid postoperative recovery and improve vision. In these cases a large diameter lens is preferable to bridge the graft and host/donor junction. Expect to see significant toricity in most grafts.

LASIK induced ecstasia

Lasik procedure can occasionally lead to complications such as Lasik Induced Ecstasia. This causes an outward bulging of the cornea resulting in irregular astigmatism and poor vision and usually happens when the cornea is not thick enough to leave an adequate stromal bed following Lasik treatment.

Rose K2 IC Fitting Guidelines

Initial Base Curve Selection

If the patient is already wearing RGP lens then select a base curve similar to the present lens. If the patient is not wearing an RGP lens then take the K readings and select a trial lens 0.2mm steeper than the average of the two K readings. If using topography then start with a trial lens close to the measurement at the temporal 4-5mm position. This is only an initial indication as to what trial lens to first select.

Central Fit

Allow the lens to settle for a few minutes and ignore the peripheral fit at this stage. Evaluate the lens fit immediately after a blink when the lens is centred. A light central touch is the goal. A slightly flatter fit is more desirable then a steeper fit as the central touch is spread over a larger area and the cornea does not erode as much in normal keratoconus. With Lasik cases some central pooling over the ablation area will be present because of the significant flattening. Even with reverse geometry lenses this central pooling often has to be accepted.

Peripheral Fit

Once a good central fit has been achieved then assess the peripheral fit. The ideal fluorescein band width at the edge of lens will be 0.5mm to 0.7mm. This may not be uniform around the whole diameter of the lens, but it should not display excessive lift off or excessive sealing in any one area. By ordering increased or decreased edge lift the optimal fluorescein band width can be achieved. For asymmetric edge lift differences a toric periphery can be ordered. For significant edge lift stand off usually inferiorly, an ACT (Asymmetric Cornea Technology) lens can be ordered.

Diameter

The standard diameter is 11.4mm. Selecting the correct diameter will help lens location. Increasing the overall diameter will nearly always help improve lens location, however, ensure that the lens is not too large to impinge on the upper sclera.

Power Evaluation

Perform over refraction in a well illuminated room. Over refract using $\pm 1.00D$ steps initially and then refine with 0.50D and 0.25D steps. Include evaluation of residual astigmatism.

Fitting Pearl

Lens location is the biggest issue with the irregular cornea. Poor, usually inferior location can be remedied by using a combination of diameter and edge lift changes. These are your greatest tools in solving this common problem.